MULTIFOCAL RETINAL CONTRACTION IN MACULAR PUCKER ANALYZED BY COMBINED OPTICAL COHERENCE TOMOGRAPHY/SCANNING LASER OPHTHALMOSCOPY

PRIYA GUPTA, BS,*† ALFREDO A. SADUN, MD, PHD,†
J. SEBAG, MD, FACS, FRCOPHTH*†

Purpose: To characterize the topography of macular pucker using coronal plane imaging in vivo, and correlate this with transverse optical coherence tomography (OCT) to assess the relationship between topographic features and severity of disease.

Methods: Forty-four eyes with macular pucker underwent full ophthalmologic evaluation including B-scan ultrasonography as well as coronal and transverse plane imaging with combined OCT/scanning laser ophthalmoscopy (SLO).

Results: Posterior vitreous detachment was present in 37/44 eyes (84.1%) by ultrasound. Multiple foci of retinal contraction were detected in 20/44 eyes (45.5%) by coronal plane OCT/SLO. Intraretinal cysts were present in 6/9 (66.7%) eyes with three or four contraction centers as compared to 10/35 (28.6%) eyes with one or two contraction centers ($P = 0.05$). Eyes with three or four contraction centers had significantly ($P = 0.05$) thicker maculae (369 $\pm$ 98 μm) compared to those with one or two contraction centers (297 $\pm$ 110 μm).

Conclusion: Coronal plane imaging detected multifocality in nearly half of eyes with macular pucker. Eyes with multiple retinal contraction centers had greater retinal damage compared to eyes with one or two contraction centers. Multifocal retinal contraction may have clinical significance in that it may impact on prognosis and management.

RETINA 28:447–452, 2008

Premacular membranes cause vision loss via membrane contraction which distorts the macula (pucker), inducing metamorphopsia and at times macular edema and thickening. The pathogenesis of macular pucker remains unclear. Sebag[1] has described that anomalous posterior vitreous detachment (PVD) with vitreoschisis may be the first step in a sequence of events that involves cell migration and proliferation at the vitreoretinal interface.[2] The surface topography of macular pucker has not been extensively characterized beyond describing global and focal adherence patterns.[3–5] In particular, the possible existence of multiple centers undergoing retinal contraction has never been systematically studied. To date, the topographic features of the vitreoretinal interface in macular pucker have not been considered important in describ-

From *VMR Institute, Huntington Beach; and †Doheny Eye Institute, University of Southern California Keck School of Medicine, Los Angeles.

None of the authors has a proprietary interest in this study.

Presented as a paper at the 19th Annual Western Retina Study Club Meeting; Pasadena, California; March 17, 2007.

Reprint requests: J. Sebag, MD, FACS, FRCOphth, VMR Institute, 7677 Center Avenue, Suite 400, Huntington Beach, CA 92647. e-mail:jsebag@VMRinstitute.com

ing this disease and prevailing classification systems[6,7] make no mention of the number of pucker centers. In fact, there is no information regarding the relationship of disease severity with the number of retinal contraction centers.

In this study, coronal plane imaging was used to search for multifocal retinal contraction and the findings were correlated with the presence or absence of intraretinal cysts and the degree of macular thickening. It was hypothesized that a significant number of patients with macular pucker have more than one center of retinal contraction and that the existence of multiple foci of retinal contraction is associated with more severe disease, as manifested by the presence of intraretinal cysts and macular edema with thickening.

Patients and Methods

Subjects

Between November 2005 and November 2006, 106 eyes in 84 patients were diagnosed with a premacular membrane based upon a comprehensive vitreoretinal consultation at the VMR Institute in Huntington Beach, CA. This included Snellen visual acuity, slit-lamp biomicroscopy with fundus evaluation (90 diopter lens), and dilated fundus examination with binocular indirect ophthalmoscopy. Subjects were excluded on the basis of confounding retinal pathology as follows: diabetic retinopathy (n = 31); a history of intravitreal injection or laser treatment for macular edema (n = 13); a history of vitreoretinal surgery (n = 11); retinal vein occlusion (n = 4); macular hole (n = 3).

There were 44 eyes in 37 patients with the sole diagnosis of premacular membrane with macular pucker (21 men [56.8%], 16 women [43.2%]; average age of 65.3 years [SD = 7.7 years]). The retrospective analysis conducted in this study was approved by the Institutional Review Board of St. Joseph Hospital, Orange, CA.

Ultrasonography

Ultrasonography was performed with a high gain, real time ultrasound device (10 mgHz probe; Quantel, Bozeman, MT) using a through-the-lid contact technique with two central (through-the-lens) views: one horizontal and one vertical. The location of the posterior vitreous cortex was determined during ocular saccades.

Optical Coherence Tomography/Scanning Laser Ophthalmoscopy (OCT/SLO)

En face imaging by combined OCT/SLO (OTI, Toronto) produces both a black and white confocal SLO fundus image (Figure 1A) and a color OCT image in the coronal plane (Figure 1C). Coronal plane images can be overlaid upon the SLO fundus images resulting in superimposed images with point-to-point registration between the SLO images and the OCT images (Figure 1B). Superimposed images were used to identify the number of pucker centers, defined as a focus of retinal contraction into which radially oriented striations converged. Figure 2 illustrates the findings used to determine the presence of one to four pucker centers.

Transverse plane (cross-sectional) OCT images were obtained in each eye and analyzed in grayscale for optimal discrimination of tissue detail.[8] These images were used to determine the presence or absence of intraretinal cysts (Figure 3) and to measure macular thickness. In four eyes, the presence of a pseudohole in the central macula made accurate measurement of foveal thickness unreliable due to constriction of the foveal tissue, and thus these eyes (three with one or two retinal contraction centers and one with three or four retinal contraction centers) were

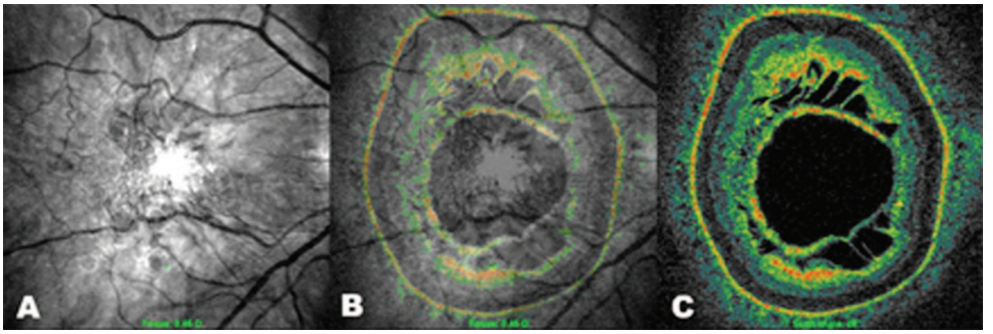

Fig. 1. To determine number of retinal contraction centers, the overlay image **(B)** was used to identify the number of pucker centers. **A,** Black and white scanning laser ophthalmoscopy (SLO) image of the fundus in a subject's right eye. **B,** Overlay of the coronal optical coherence tomography (OCT) image superimposed upon the SLO fundus image with point-to-point registration. **C,** Coronal plane OCT image, in color.

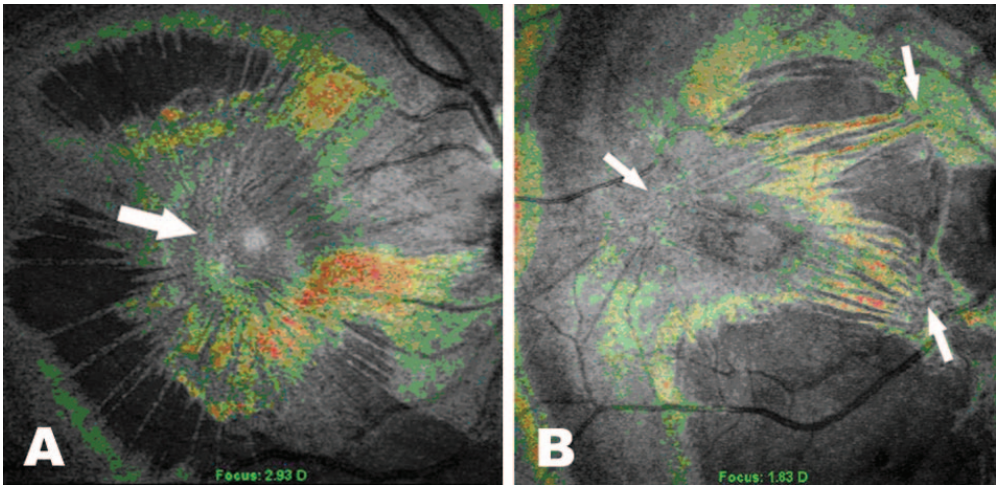

Fig. 2. Coronal plane optical coherence tomography image superimposed upon scanning laser ophthalmoscopy fundus image of a macular pucker with **(A)** only one center of retinal contraction and **(B)** three centers of retinal contraction.

excluded from the quantitative analysis of central macular thickness.

Retinal thickness was measured at the foveola, when identifiable on transverse OCT imaging. In the presence of macular edema that precluded accurate identification of the fovea, however, the intersection feature of the OCT/SLO software was used to define the central point of measurement. As shown in Figure 4, this program creates a three-dimensional representation of the transverse OCT image intersected with the SLO fundus image at the exact location in the fundus where the transverse OCT image was obtained. The light reflex at the center of the SLO image corresponds to the point of fixation at the central macula, and the point of the OCT image that intersected with this light reflex was used as the site for the retinal thickness measurements. Using the calibrated calipers of the OCT/SLO software (Figure 5), central macular thickness was measured from the internal limiting lamina of the retina to the anterior aspect of the outer layer of the double laminar structure representing the choriocapillaris/retinal pigment epithelium interface.[9] The premacular membrane itself was not included in the measurement of central macular thickness. In each eye, multiple measurements (mean ± SD = 10 ± 5 images measured) were made on different transverse OCT images at each of 4 axes (0°, 45°, 90°, and 135°; see Figure 5), and an average of the retinal thickness measurements was computed for each plane. An overall average was computed from these four averages (one for each plane), yielding the value used in statistical analyses.

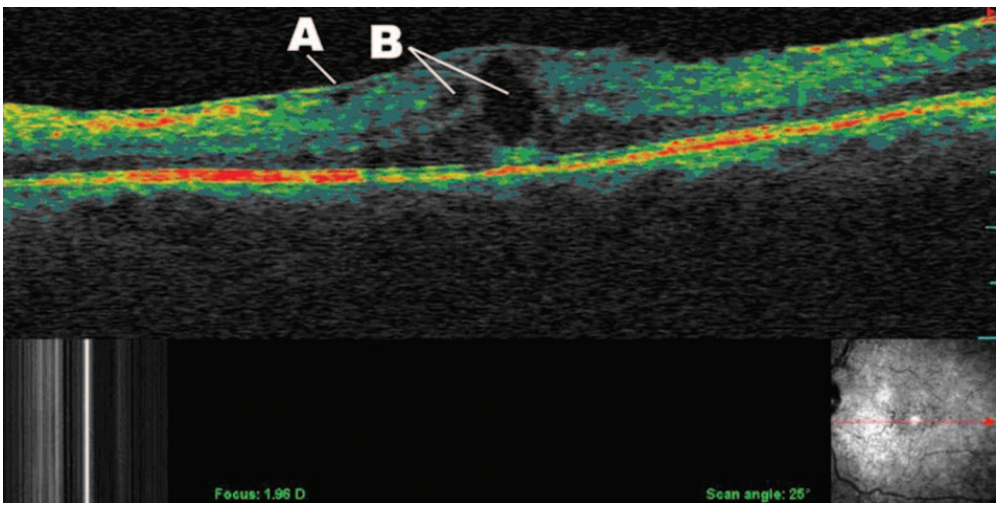

Fig. 3. Transverse optical coherence tomography image demonstrating a premacular membrane with **(A)** macular pucker and **(B)** intraretinal cysts.

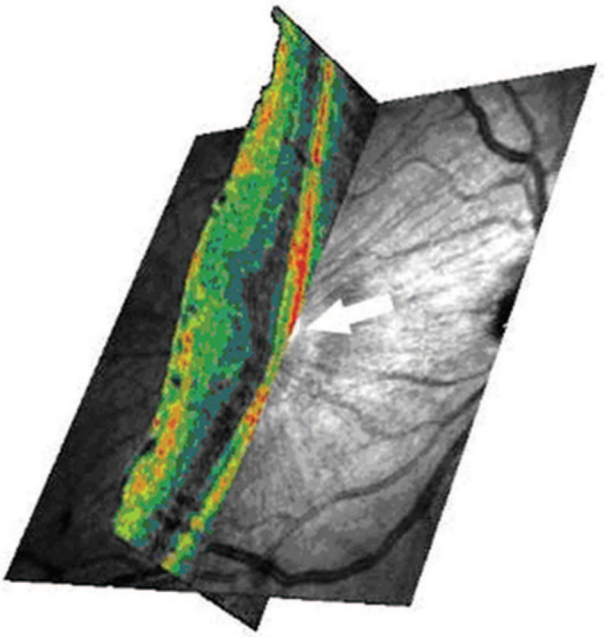

Fig. 4. Three-dimensional reconstruction of a transverse optical coherence tomography (OCT) image at 90° intersecting with the SLO fundus image. The central light reflex (arrow) on the scanning laser ophthalmoscopy fundus image was used to identify the center of the macula on the OCT image for central retinal thickness measurement.

Statistical Analyses

Fisher exact test and the two-sample *t*-test assuming equal variance were used to evaluate the statistical significance of differences found in this study, using Microsoft Excel.

Results

PVD was detected by ultrasonography in 37/44 (84.1%) eyes. OCT/SLO coronal plane imaging identified that 24/44 (54.5%) eyes had only one retinal contraction center (Figure 2A). Eyes with multiple foci of contraction had two, three, or four centers of retinal contraction. Eleven eyes (25%) demonstrated two pucker centers, 5 eyes (11.4%) showed three pucker centers (Figure 2B), and 4 eyes (9.1%) had four pucker centers.

Subjects were divided into two groups for transverse plane OCT analyses. The eyes with one and two retinal contraction centers were classified as "simple pucker" (n = 35, Figure 2A), while the eyes with three or more contraction centers were classified as "complex pucker" (n = 9, Figure 2B). There was no difference in visual acuity between the two groups (Table 1). PVD by ultrasonography was present in 29/35 (82.9%) eyes with simple pucker, and 8/9 (88.9%) eyes with complex pucker also had a PVD, a difference which was not statistically significant (Table 1). However, only 10/35 (28.6%) eyes with simple pucker had intraretinal cysts, while 6/9 (66.7%) eyes with complex pucker had intraretinal cysts ($P = 0.05$; Fisher exact test). Central macular thickness in 32 eyes with simple pucker was 297 ± 110 μm, while macular thickness in 8 eyes with complex pucker was 369 ± 98 μm, a 24% increase that was statistically significant ($P = 0.05$; two-sample *t*-test assuming equal variance).

Discussion

OCT/SLO imaging is a new combination of technologies that provides coronal plane images of the vitreoretinal interface. The precision made possible by the point-to-point registration between the coronal and transverse plane images allows for exact comparisons of the coronal views with conventional transverse OCT images. In this study, automated measurement of macular thickness was not employed, due to evidence that it underestimates the true value.[10]

This study found that nearly half of all patients with macular pucker have more than one site of retinal contraction, a finding that has not been appreciated in previous studies. While the existence of multifocal vitreoretinal attachments has been previously identified by OCT alone,[5] the presence of retinal contraction at these sites was not recognized. This furthermore appears to be the first study to quantify the number of pucker centers, largely due to the availability of coronal plane imaging technology.

The exact pathologic processes at the vitreoretinal interface that lead to multicentric macular pucker remains unknown. Anomalous PVD with vitreoschisis[1] may play a predominant role in unifocal macular pucker. Perhaps the migration and proliferation of glial and other cells from the retina may play a more prominent role in the pathogenesis of multifocal macular pucker.[2] That anomalous PVD is probably an inciting event in both instances, however, is supported by the finding of PVD by ultrasound in 84% of the cases reported herein, which is comparable to other studies.[11,12] Furthermore, there was no difference in PVD prevalence between simple and complex pucker, further supporting the concept that anomalous PVD is the inciting event in each case.

The presence of multifocal retinal contraction may have clinical significance. There are considerably more cases of intraretinal cysts and more macular thickening in eyes with multiple foci of retinal contraction, suggesting that multifocal macular pucker induces greater retinal damage. This may be due to greater tangential traction between multiple pucker

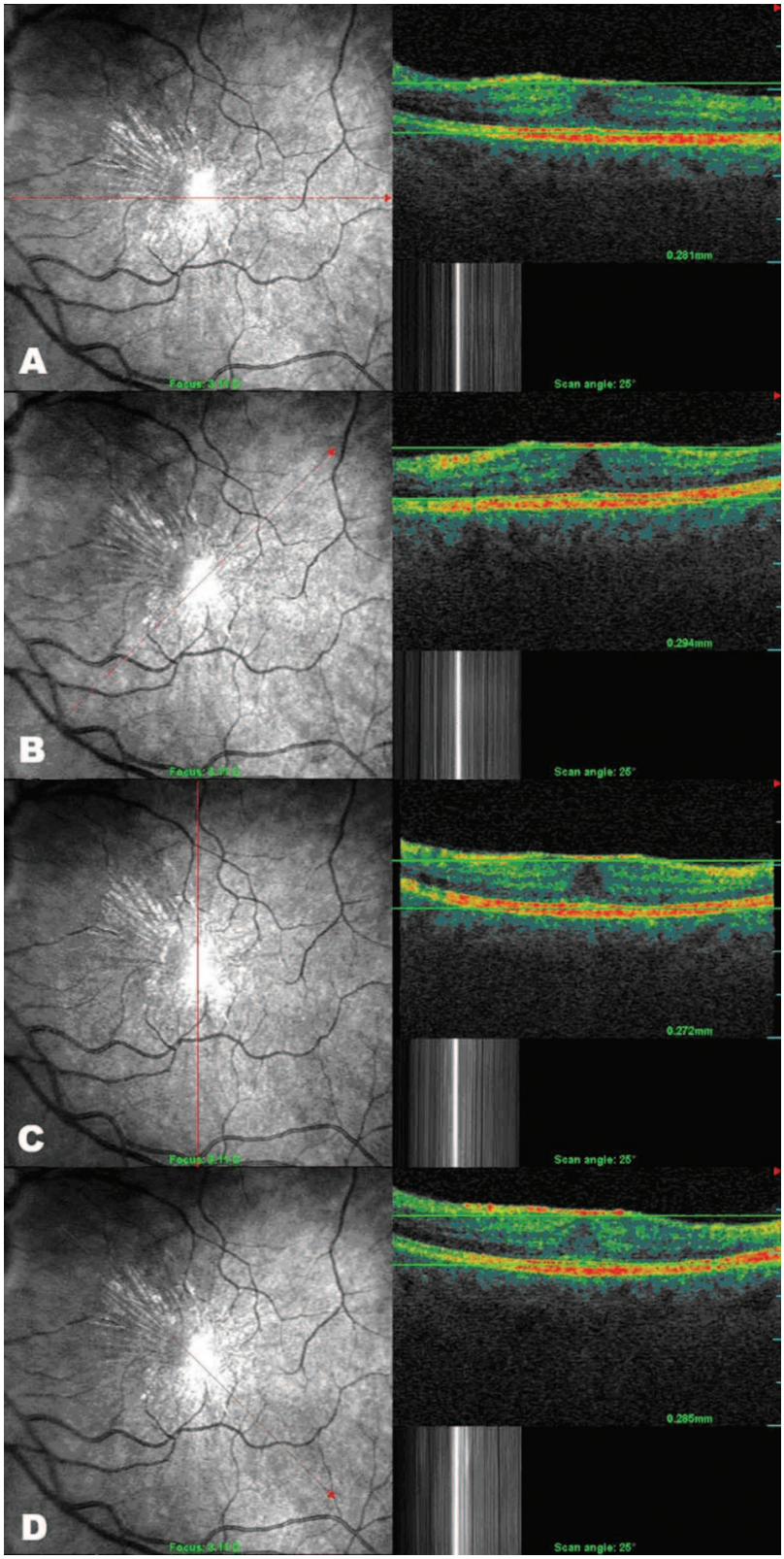

Fig. 5. Axial optical coherence tomography images in four different planes yielding retinal thickness measurements that were averaged. **A,** Image at 0° with a retinal thickness of 281 μm. **B,** Image at 45° with a retinal thickness of 294 μm. **C,** Image at 90° with a retinal thickness of 272 μm. **D,** Image at 135° with a retinal thickness of 285 μm.

Table 1. Findings in Simple Pucker versus Complex Pucker

	Simple Pucker (n = 35)	Complex Pucker (n = 9)	*P* Value
Cysts	10/35 (28.6%)	6/9 (66.7%)	0.05
Macular thickness (μm)	297	369	0.05
Visual acuity	20/29.5	20/29.4	NS
PVD (ultrasound)	29/35 (82.9%)	8/9 (88.9%)	NS

NS = not statistically significant; PVD = posterior vitreous detachment.

centers inducing more widespread and profound retinal damage than in cases with only one pucker center.

What is difficult to reconcile, however, is that visual acuity is not more affected in eyes with three or four centers of retinal contraction as compared to one or two. It may be that the structural findings in the more affected patients have not yet impacted on function and may do so with time. Future longitudinal studies may be helpful in testing this hypothesis. Another possibility is that measuring visual acuity may not be the best way to assess the functional abnormalities induced by macular pucker. Wall and Sadun[13] described that measuring visual acuity alone can often be quite misleading, since this only assesses the best single spot on the retina, chosen by patient fixation. According to these authors, significant damage to the retina could be missed if the only outcome measure is visual acuity. Thus, alternative outcome measures such as contrast sensitivity, an inner retinal function, may be more revealing. Of great interest would be the development of a quantitative measure of metamorphopsia, as this will likely provide more telling visual assessment than visual acuity.

Key words: anomalous PVD, intraretinal cysts, macular pucker, macular thickening, OCT, SLO.

References

1. Sebag J. Anomalous posterior vitreous detachment: a unifying concept in vitreo-retinal disease. Graefes Arch Clin Exp Ophthalmol 2004;242:690–698.
2. Vinores SA, Campochiaro PA, Conway BP. Ultrastructural and electron-immunocytochemical characterization of cells in epiretinal membranes. Invest Ophthalmol Vis Sci 1990;31:14–28.
3. Wilkins JR, Puliafito CA, Hee MR, et al. Characterization of epiretinal membranes using optical coherence tomography. Ophthalmology 1996;103:2142–2151.
4. Mori K, Gehlbach PL, Sano A, et al. Comparison of epiretinal membranes of differing pathogenesis using optical coherence tomography. Retina 2004;24:57–62.
5. Gallemore RP, Jumper JM, McCuen BW, et al. Diagnosis of vitreoretinal adhesions in macular disease with optical coherence tomography. Retina 2000;20:115–120.
6. Gass JDM. Stereoscopic Atlas of Macular Diseases: Diagnosis and Treatment, Vol 2. St. Louis: Mosby, 1997;938–940.
7. Foos RY. Nonvascular proliferative extraretinal retinopathies. Am J Ophthalmol 1978;86:723–725.
8. Ishikawa H, Gürses-Ozden R, Hoh ST, et al. Grayscale and proportion-corrected optical coherence tomography images. Ophthalmic Surg Lasers 2000;31:223–228.
9. Pons ME, Garcia-Valenzuela E. Redefining the limit of the outer retina in optical coherence tomography scans. Ophthalmology 2005;112:1079–1085.
10. Costa RA, Calucci D, Skaf M, et al. Optical coherence tomography 3: Automatic delineation of the outer neural retinal boundary and its influence on retinal thickness measurements. Invest Ophthalmol Vis Sci 2004;45:2399–2406.
11. Roth AM, Foos RY. Surface wrinkling retinopathy in eyes enucleated at autopsy. Trans Am Acad Ophthalmol Otolaryngol 1977;75:1047–1058.
12. Sidd RJ, Fine SL, Owens SL, Patz A. Idiopathic preretinal gliosis. Am J Ophthalmol 1982;94:44–48.
13. Wall M, Sadun AA. New Methods of Visual Clinical Testing. Springer-Verlag; New York: 1985.