VITREO-PAPILLARY ADHESION IN MACULAR HOLE AND MACULAR PUCKER

MICHELLE Y. WANG, BS,*† DIEUTHU NGUYEN, MD,*
NAREEN HINDOYAN, BA,* ALFREDO A. SADUN, MD, PHD,†
JERRY SEBAG, MD, FACS, FRCOPHTH*†

Purpose: Vitreo-macular pathology may be influenced by vitreo-papillary adhesion (VPA). Optical coherence tomography/scanning laser ophthalmoscopy (OCT/SLO) was used to identify VPA in full-thickness macular hole, lamellar hole, and macular pucker (MP).

Methods: Ultrasonography and OCT/SLO were performed in 55 subjects: 16 with macular hole, 11 with lamellar hole, and 28 with MP. The main outcome measures were the presence of posterior vitreous detachment by ultrasound, and the findings of VPA and intraretinal cysts by OCT/SLO.

Results: Posterior vitreous detachment was detected by ultrasound in 26/28 (92.9%) eyes with MP, 6/11 (54.5%) eyes with lamellar hole ($P < 0.05$), and 4/16 (25%) eyes with macular hole ($P < 0.00001$). Optical coherence tomography/scanning laser ophthalmoscopy detected VPA in 14/16 (87.5%) macular hole eyes, 4/11 (36.4%) lamellar hole eyes ($P < 0.05$), and 5/28 (17.9%) MP eyes ($P < 0.00005$). Intraretinal cysts were present in 4/5 (80%) MP eyes with VPA but only 1/23 (4.3%) MP eyes without VPA ($P < 0.005$).

Conclusion: Vitreo-papillary adhesion was significantly more common in full-thickness macular hole than lamellar hole or MP. When present in MP, VPA was frequently associated with intraretinal cysts. Hence, VPA may have an important influence on the vectors of force at the vitreo–retinal interface inducing holes and cysts.

RETINA 29:644–650, 2009

Macular hole (MH) and macular pucker (MP) have long been considered distinct clinical entities. Many studies and speculations over the past two decades have suggested the etiology to be multifactorial. Sebag has proposed that anomalous posterior vitreous detachment (PVD), which results from gel liquefaction in the absence of concurrent dehiscence at the vitreo–retinal interface, plays a key pathogenic role in these diseases.[1] Indeed, vitreoschisis, which is a split in the posterior vitreous cortex that results from anomalous PVD, is known to occur in MHs and MPs.[2,3] When anomalous PVD involves persistent adherence at the optic disk, vitreo-papillary adhesion (VPA) can cause optic nerve dysfunction[4] and macular edema.[5] What is not known is whether VPA is present in full-thickness and lamellar MHs, as well as MP and whether the presence or absence of VPA could account for the different pathologies in these diseases. Moreover, while intraretinal cysts are known to occur in various maculopathies,[6–13] the association between VPA and cysts in these diseases has not yet been investigated. It is plausible that in vitreo-maculopathies, the vectors of force at the vitreo-retinal interface are influenced by VPA resulting in holes and intraretinal cysts. This study was designed to test the hypothesis that VPA is more commonly found in full-thickness MHs than lamellar holes (LH) and MP. It was also hypothesized that when present in MP, VPA would be more commonly associated with intraretinal cysts.

From the *VMR Institute, Huntington Beach; and †Doheny Eye Institute, University of Southern California Keck School of Medicine, Los Angeles, California.

This work was supported by the VMR Institute in Huntington Beach, CA, and an RPB Medical Student Fellowship (MYW).

This paper is based on a presentation at the annual meeting of the

Copyright © by Ophthalmic Communications Society, Inc. Unauthorized reproduction of this article is prohibited.

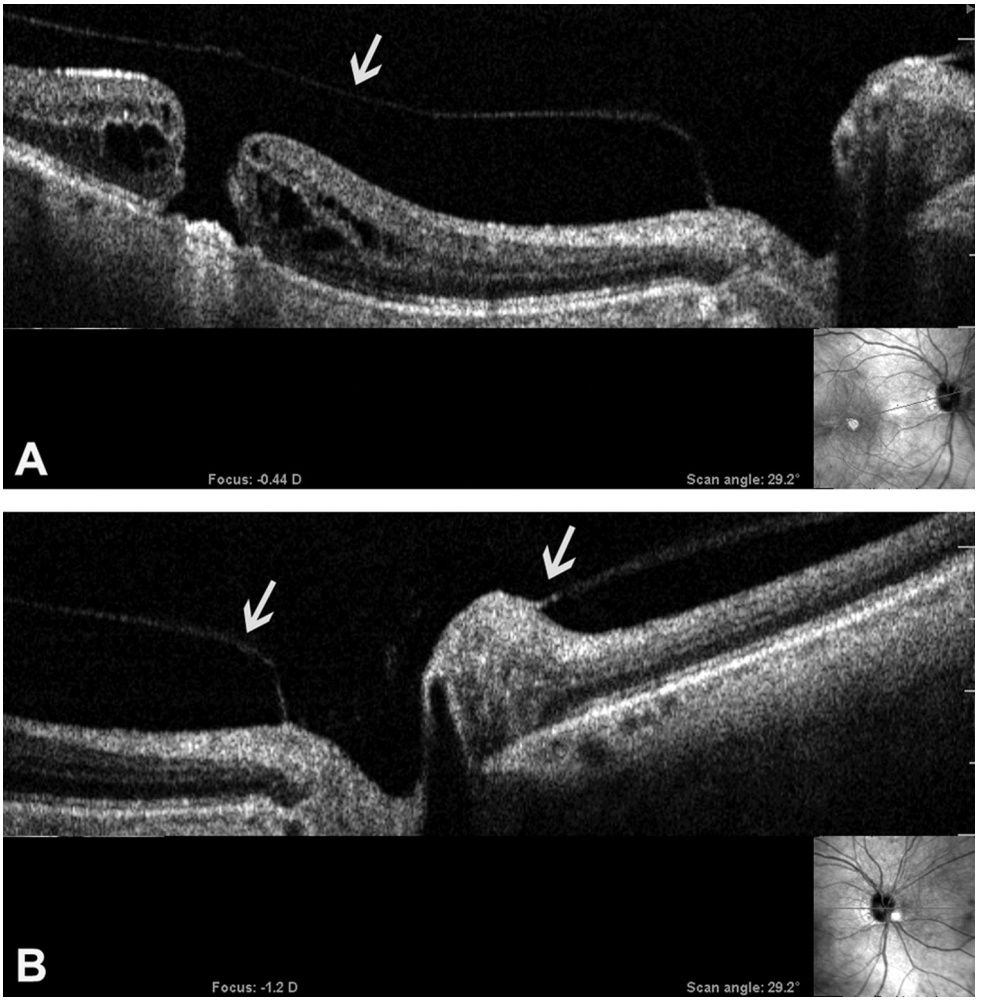

Fig. 2. A composite longitudinal OCT image (**A**) demonstrates the detachment of posterior vitreous cortex (probably only the inner layer after anomalous PVD with vitreoschisis) from the macula with persistent adhesion on both sides of the optic disk (**B**). It is possible that there is cellular proliferation on this tissue plane.

6.3 years]. The clinical characteristics of this group are shown in Table 1. The diameter of the MH ranged from 205 to 1,240 μm with a mean size of 485 μm. By clinical criteria (examination and OCT measurements of MH diameter), 8/16 (50.0%) eyes had Stage II MH, 6/16 (37.5%) had Stage III MH, and 2/16 (12.5%) had Stage IV MH. The MH stage was positively correlated with the MH diameter ($P < 0.001$).

Posterior vitreous detachment was detected by ultrasonography in 4/16 (25%) eyes. Vitreo-papillary adhesion (Figure 2) was detected by OCT/SLO in 14/16 (87.5%) eyes. Two patients had both a PVD and VPA. Intraretinal cysts surrounding the MH were found in 14/14 (100%) eyes with VPA.

Lamellar Hole

The clinical characteristics of this group are shown in Table 2. There were 11 eyes with LH [6 men (54.5%), 5 women (45.5%); average age of 67 ± 9.5 years]. Posterior vitreous detachment was detected by ultrasonography in 6/11 (54.5%) eyes. Optical coherence tomography/scanning laser ophthalmoscopy imaging detected VPA (Figure 3) in 4/11 (36.4%) eyes. No patients had both a PVD and VPA. Intraretinal cysts were detected in 3/4 (75%) eyes with VPA. Of

Table 2. Clinical Characteristics and Findings in 11 Eyes With LH

Age	Gender	Eye	BCVA	PVD	VPA	Cysts
43	F	OS	20/20	−	+	+
71	F	OD	20/30	−	+	+
68	F	OD	20/80	−	+	+
78	M	OS	20/100	−	+	−
70	M	OD	20/30−2	+	−	+
72	M	OD	20/50−2	+	−	+
71	F	OD	20/30	+	−	+
60	F	OD	20/25−3	+	−	−
60	M	OD	20/20−1	+	−	−
72	M	OD	20/60−2	+	−	−
72	M	OD	20/30−1	−	−	−

BCVA, best-corrected visual acuity; +, present; −, absent.

Copyright © by Ophthalmic Communications Society, Inc. Unauthorized reproduction of this article is prohibited.

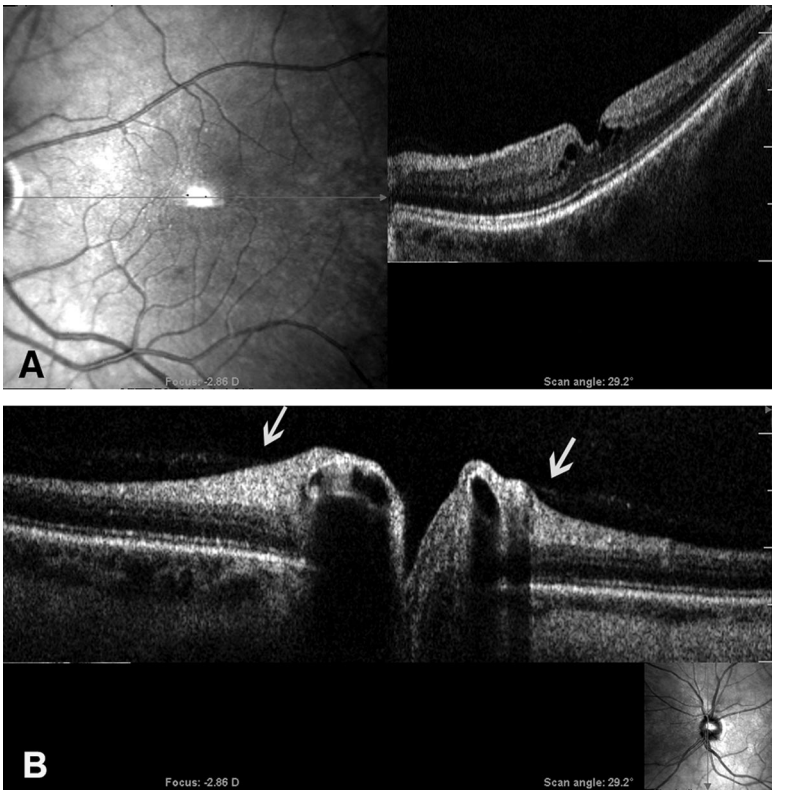

Fig. 3. Longitudinal OCT-SLO imaging demonstrates a LH with intraretinal cysts (**A**). Two bands of vitreous adhesion are evident at the margins of the optic disk (**B**).

the seven eyes without VPA, 3/7 (42.9%) had intraretinal cysts.

Macular Pucker

There were 28 eyes with Grade II MP, which appeared as wrinkling of the macula with linear striae [16 men (57.1%), 12 women (42.9%); average age of 69.8 ± 9.2 years]. The clinical characteristics of this group are shown in Table 3. Ultrasonography detected PVD in 26/28 (92.9%) eyes. Optical coherence tomography/scanning laser ophthalmoscopy imaging identified VPA in 5/28 (17.9%) eyes. As shown in Table 3, 4/26 (15.3%) patients had both a PVD by ultrasound and VPA by OCT/SLO, suggesting that ultrasonography was not able to detect anomalous PVD with VPA in these cases. Of the 5 eyes with MP and VPA, intraretinal cysts (Figure 4) were present in 4 eyes (80%) compared with only 1 of the 23 (4.3%) eyes with MP but no VPA ($P < 0.005$).

Discussion

This study determined that VPA is far more prevalent in full-thickness MHs than LHs and MPs [MH = 87.5% versus LH = 36.4% ($P < 0.05$) and versus MP = 17.9% ($P < 0.00005$)] (Figure 5), suggesting that VPA is associated with MHs. The possible mech-

Table 3. Clinical Characteristics and Findings in 28 Eyes With MP

Age	Gender	Eye	BCVA	PVD	VPA	Cysts
67	M	OD	20/30−1	+	+	+
84	M	OD	20/140	+	+	+
61	F	OD	20/50	NA	+	+
89	M	OD	20/26−3	+	+	+
64	F	OD	20/140+1	+	+	−
85	M	OS	20/100−2	+	−	+
56	F	OS	20/40	+	−	−
67	M	OD	20/40−1	+	−	−
74	F	OS	20/30	+	−	−
71	M	OD	20/26+3	+	−	−
73	M	OS	20/32−2	+	−	−
57	M	OD	20/30+2	+	−	−
77	F	OS	20/60−1	+	−	−
52	F	OD	20/80	+	−	−
69	M	OS	20/60	+	−	−
59	F	OS	20/20−1	+	−	−
65	F	OD	20/40−3	+	−	−
70	M	OD	20/50−2	+	−	−
75	F	OD	20/80	+	−	−
79	M	OD	20/60−2	−	−	−
71	M	OS	20/25−1	+	−	−
67	M	OS	20/80−1	+	−	−
75	M	OD	20/30+1	+	−	−
59	M	OD	20/40	+	−	−
69	F	OD	20/50−1	+	−	−
65	F	OS	20/20	+	−	−
82	M	OD	20/100	+	−	−
72	F	OS	20/40−2	+	−	−

BCVA, best-corrected visual acuity; NA, not available; +, present; −, absent.

Copyright © by Ophthalmic Communications Society, Inc. Unauthorized reproduction of this article is prohibited.

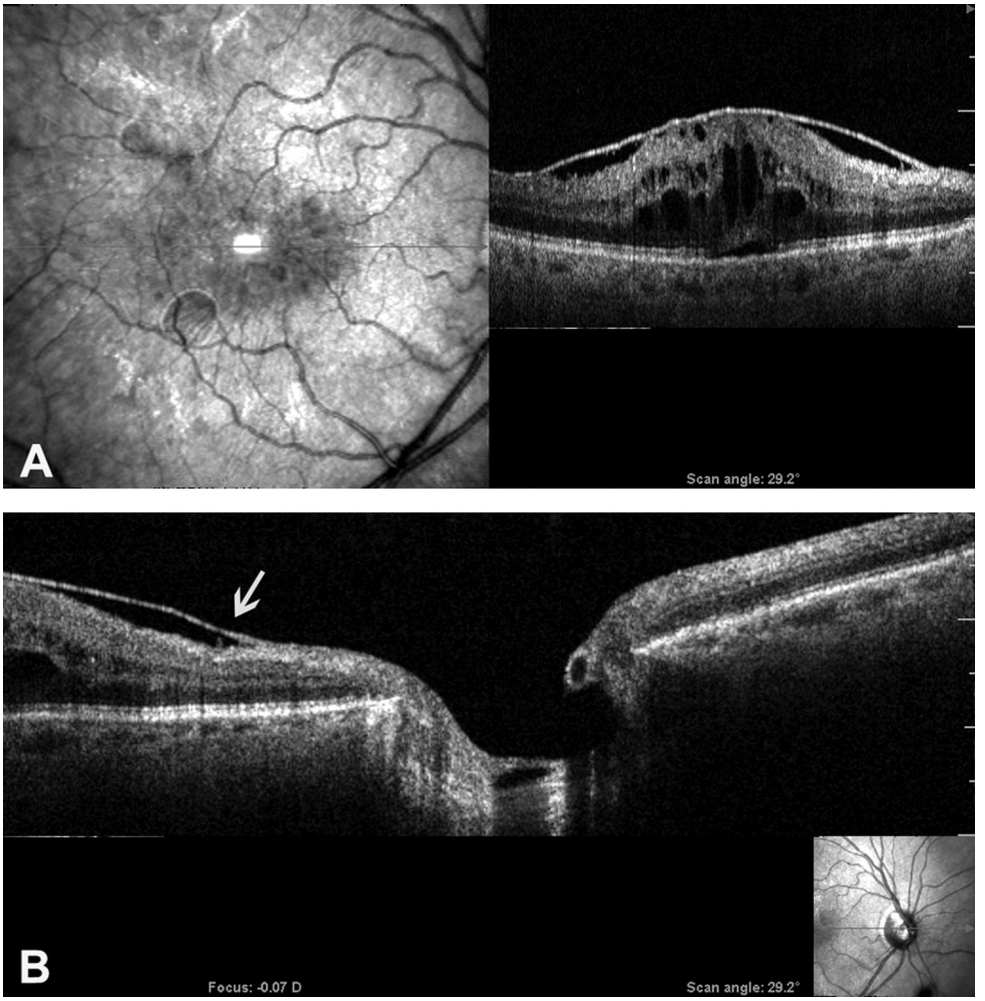

Fig. 4. Longitudinal OCT/SLO imaging demonstrates an MP with intraretinal cysts (**A**) and VPA at the margin of the optic disk (**B**).

anism by which this happens likely involves anomalous PVD,[1] which has been proposed as the first event in the pathophysiology of both MH and MP.[3,6,18] Indeed, while the finding of PVD by ultrasonogarphy in 92.9% of subjects with MP confirms many previous studies, the existence of a premacular membrane with pucker in these cases suggests that this PVD is anomalous with persistent adherence of the posterior layer

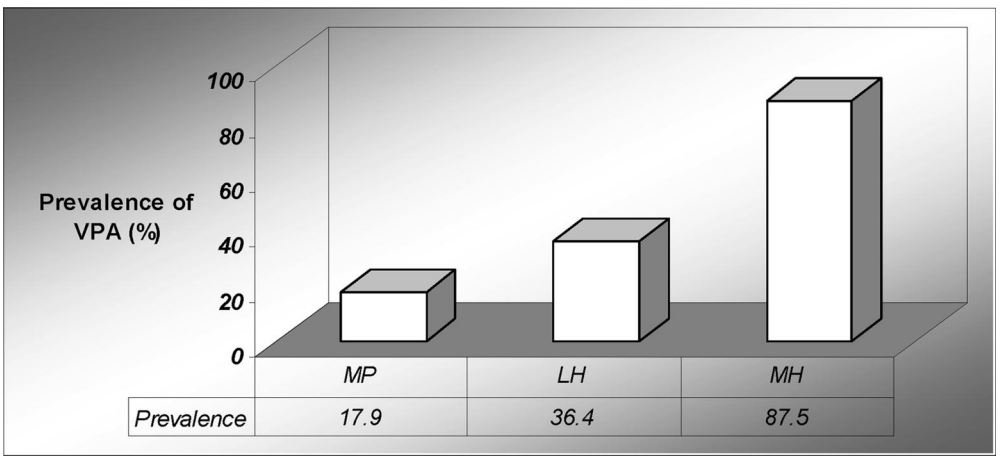

Fig. 5. VPA was found more often in MH than LH ($P < 0.05$) and MP ($P < 0.00005$), suggesting that VPA may contribute to the formation of MHs.

Copyright © by Ophthalmic Communications Society, Inc. Unauthorized reproduction of this article is prohibited.

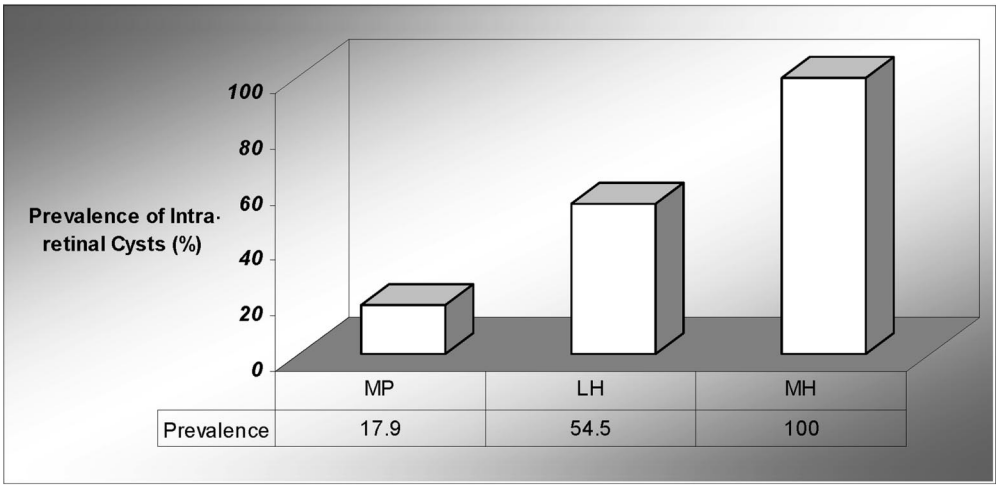

Fig. 6. Intraretinal cysts were more common in MHs compared with LHs ($P < 0.01$). Moreover, LHs were more commonly associated with intraretinal cysts than MP eyes ($P < 0.05$).

of vitreoschisis[3] to the retina. This thin tissue is detectable only by OCT.

After anomalous PVD with vitreoschisis,[2,3] the outer layer of the split posterior vitreous cortex remains attached to the macula. In the absence of VPA, inward (centripetal) tangential traction by this outer layer of the split posterior vitreous cortex likely throws the underlying retina into folds, resulting in MP. If vitreous is still attached to the optic disk, however, the vectors of force could be changed, resulting in outward (centrifugal) tangential traction that induces central retinal dehiscence and MH formation. Indeed, papillo-foveal traction has previously been implicated in the pathogenesis of MHs.[19] Hence, while anomalous PVD may be the initial event, the presence or absence of VPA may influence the subsequent course and vectors of traction. The results of this study suggest that in the absence of VPA, an MP is more likely to be present. In the presence of VPA, an MH is more likely to occur, with LH possibly representing an intermediate stage in lead to full-thickness MH formation. In fact, previous studies[6] have suggested that LHs represent an "abortive" process of MH formation,[16] and that foveal pseudocysts with partial PVD become LHs if the base is preserved and full-thickness MHs if the outer retinal layer is disrupted.[8]

Another aspect to consider is the issue of intraretinal cysts. Foveal cysts are believed to be the precursors of either full-thickness MHs or LHs.[6,8,9] In fact, every single MH in this study with VPA (14/14; 100%) was associated with intraretinal cysts, which was significantly more often than in LHs ($P < 0.01$). This study also determined that intraretinal cysts were found more commonly in LHs than in eyes with MP ($P < 0.05$) (Figure 6). MH and LH may have more cysts compared with MP because the inner layers of the retina are severely disrupted by changing fluid

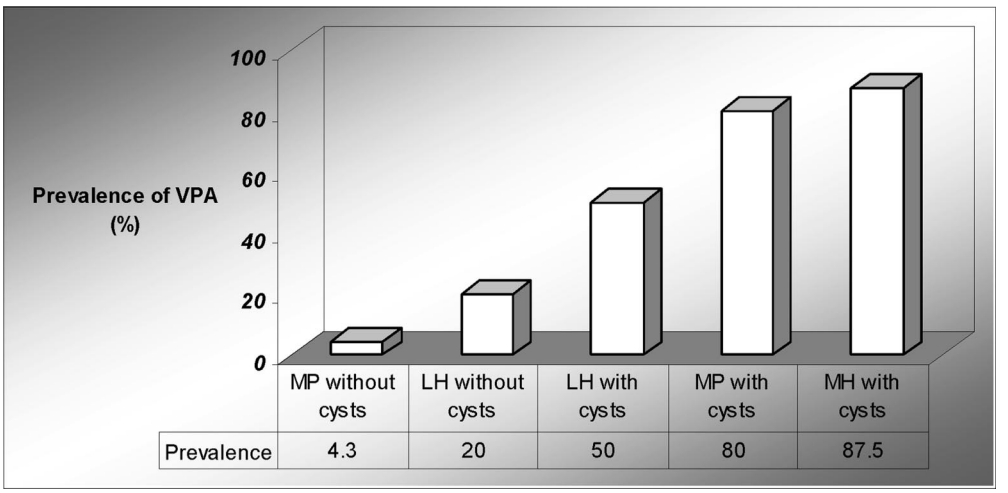

Fig. 7. The prevalence of VPA increased from very low in MP without cysts and LH without cysts, to intermediate in LH with cysts, and was very high in MP with cysts and MH with cysts.

Copyright © by Ophthalmic Communications Society, Inc. Unauthorized reproduction of this article is prohibited.

dynamics. But a significantly higher incidence of cysts was found in MP when VPA was present (4/5 = 80%) compared with when there was no VPA in MP (1/23 = 4.3%; $P < 0.005$). Therefore, our findings suggest that VPA may not only be associated with LH and MH, but may also contribute to the formation of intraretinal cysts in the presence of traction. Indeed, from this perspective, vitreo-maculopathies can be grouped according to the presence or absence of intraretinal cysts. Macular hole with cysts had VPA in 87.5%, MP with cysts had VPA in 80%, and LHs with cysts had VPA in 50% of cases. This was far greater than LHs without cysts (VPA in 20%), and MP without cysts (4.3%) (Figure 7). It would thus appear that VPA is important in this group of diseases, probably by influencing the vectors of traction force at the vitreo-retinal interface.

In conclusion, the findings support the hypothesis that VPA is significantly more common in full-thickness MH than in both LH and MP. When present in MP, VPA is strongly associated with intraretinal cysts. Vitreo-papillary adhesion is more common in MP and MH with cysts compared with LH and MP without cysts. Thus, while VPA is known to play a role in certain papillopathies,[4,5,20,21] and especially in diabetic vitreo-retinopathy,[22] it may also be important in vitreo-maculopathies.

Key words: anomalous posterior vitreous detachment, intra-retinal cyst, lamellar hole, macular hole, macular pucker, optical coherence tomography, scanning laser ophthalmoscopy, vitreo-papillary adhesion, vitreous.

Acknowledgments

Laurie LaBrie of USC assisted with the statistical analyses in this study.

References

1. Sebag J. Anomalous posterior vitreous detachment: a unifying concept in vitreo-retinal disease. Graefes Arch Clin Exp Ophthalmol 2004;242:690–698.
2. Sebag J. Vitreoschisis. Graefes Arch Clin Exp Ophthalmol 2008;246:329–332.
3. Sebag J, Gupta P, Rosen R, Garcia P, Sadun AA. Macular holes and macular pucker: the role of vitreoschisis as imaged by optical coherence tomography/scanning laser ophthalmoscopy. Trans Am Ophthalmol Soc 2007;105:121–131.
4. Sebag J. Vitreopapillary traction as a cause of elevated optic nerve head. Am J Ophthalmol 1999;128:261–262.
5. Karatas M, Ramirez JA, Ophir A. Diabetic vitreopapillary traction and macular oedema. Eye 2005;19:676–682.
6. Gaudric A, Haouchine B, Massin P, Paques M, Blain P, Erginay A. Macular hole formation: new data provided by optical coherence tomography. Arch Ophthalmol 1999;117:744–751.
7. Takahashi H, Kishi S. Tomographic features of a lamellar macular hole formation and a lamellar hole that progressed to a full-thickness macular hole. Am J Ophthalmol 2000;130:677–679.
8. Haouchine B, Massin P, Gaudric A. Foveal pseudocyst as the first step in macular hole formation: a prospective study by optical coherence tomography. Ophthalmology 2001;108:15–22.
9. Jaffe GJ, Caprioli J. Optical coherence tomography to detect and manage retinal disease and glaucoma. Am J Ophthalmol 2004;137:156–169.
10. Kishi S, Kamei Y, Shimizu K. Tractional elevation of Henle's fiber layer in idiopathic macular holes. Am J Ophthalmol 1995;120:486–496.
11. Reese AB, Jones IS, Cooper WC. Macular changes secondary to vitreous traction. Am J Ophthalmol 1967;64:544–549.
12. McDonnell PJ, Fine SL, Hillis AI. Clinical features of idiopathic macular cysts and holes. Am J Ophthalmol 1982;93:777–786.
13. Morgan CM, Schatz H. Involutional macular thinning: a premacular hole condition. Ophthalmology 1986;93:153–161.
14. Gass JD. Reappraisal of biomicroscopic classification of stages of development of a macular hole. Am J Ophthalmol 1995;119:752–759.
15. Gass JDM. Stereoscopic Atlas of Macular Diseases: Diagnosis and Treatment. Vol 2. St. Louis: Mosby; 1997;938–940.
16. Haouchine B, Massin P, Tadayoni R, Erginay A, Gaudric A. Diagnosis of macular pseudoholes and lamellar macular holes by optical coherence tomography. Am J Ophthalmol 2004;138:732–739.
17. Witkin AJ, Ko TH, Fujimoto JG, et al. Redefining lamellar holes and the vitreomacular interface: an ultrahigh-resolution optical coherence tomography study. Ophthalmology 2006;113:388–397.
18. Tanner V, Chauhan DS, Jackson TL, Williamson TH. Optical coherence tomography of the vitreoretinal interface in macular hole formation. Br J Ophthalmol 2001;85:1092–1097.
19. Chauhan DS, Antcliff RJ, Rai PA, Williamson TH, Marshall J. Papillofoveal traction in macular hole formation: the role of optical coherence tomography. Arch Ophthalmol 2000;118:32–38.
20. Cibis GW, Watzke RC, Chua J. Retinal hemorrhages in posterior vitreous detachment. Am J Ophthalmol 1975;80:1043–1046.
21. Katz B, Hoyt WF. Gaze-evoked amaurosis from vitreopapillary traction. Am J Ophthalmol 2005;139:631–637.
22. Kroll P, Wiegand W, Schmidt J. Vitreopapillary traction in proliferative diabetic vitreoretinopathy. Br J Ophthalmol 1999;83:261–264.

Copyright © by Ophthalmic Communications Society, Inc. Unauthorized reproduction of this article is prohibited.